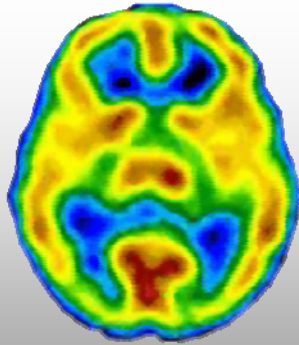
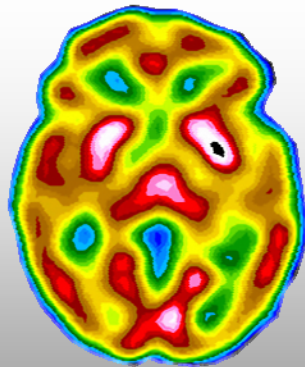


Anxiety Disorder



Normal



Anxiety Disorder

Case Study

Clinical History: The patient is a 58-year-old, married female who is a retired attorney.

Symptoms:

- Worry
- Fatigue
- General Anxiety
- Recent onset of panic attacks
- Fear in social situations
- Performance anxiety

Brain SPECT Findings: Markedly increased activity in the basal ganglia is associated with anxiety –related disorders.

CereScan Corp.
300 South Jackson Street
Denver, CO 80209

866-722-4806
CereScanImaging.com