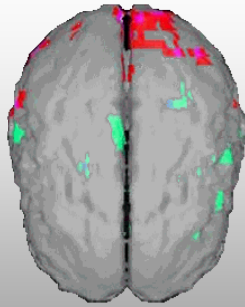
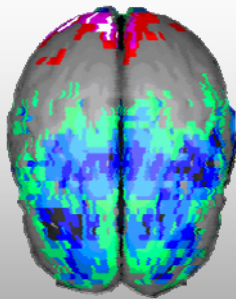


Frontotemporal Dementia



Normal



Frontotemporal Dementia

CereScan Corp.
300 South Jackson Street
Denver, CO 80209

866-722-4806
CereScanImaging.com

Case Study

Clinical History: The patient is a 64-year-old male who attended 2 years of college.

Chief Complaints: Memory problems, confusion, cognitive function and processing problems, tendency to misplace things, mood swings, some depressive and manic symptoms, problems with inattention, fidgetiness, restlessness and paranoid thoughts.

Brain SPECT Findings: The findings of significant fixed perfusion abnormalities in the frontal and temporal lobes, and apparent increased ventricle-to-brain ratio at rest, along with the patient's age and symptomatology makes a frontotemporal neurodegenerative process a possibility that needs to be explored.