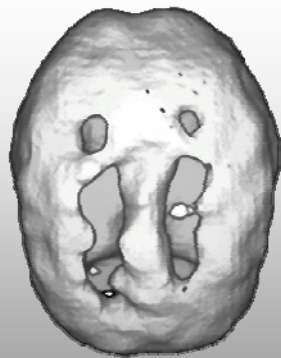


Traumatic Brain Injury



Normal



Traumatic Brain Injury

CereScan Corp.
300 South Jackson Street
Denver, CO 80209

866-722-4806
CereScanImaging.com

Case Study

Clinical History: The patient is a 56-year-old female who was in a head-on automobile collision during which she sustained a painful neck injury. Following this accident, she developed numerous cognitive processing problems, difficulty with comprehension of information and reading, memory problems, and headaches nearly everyday.

Brain SPECT Findings: The medical findings from her brain SPECT evaluation revealed abnormal hypoperfusion (low blood flow) in the cerebellum, temporal lobes, superior anterior frontal lobes, superior frontoparietal area, superior parietal lobes and inferior frontal areas, most consistent with traumatic brain injury.